

# FIRST DESCRIPTION OF A FEMALE PATIENT WITH ADVANCED ANKYLOSING SPONDYLITIS AND POLYMYALGIA RHEUMATICA — A CASE REPORT

## PRVI OPIS KOEGZISTENCIJE UZNAPREDOVALOG ANKILOZANTNOG SPONDILITISA I REUMATSKE POLIMIALGIJE KOD ŽENE – PRIKAZ BOLESNICE

Jure Aljinović<sup>1,2</sup>, Daniela Šošo<sup>1</sup>, Sanja Lovrić Kojundžić<sup>2,3,4</sup>,  
Dušanka Martinović Kaliterna<sup>4</sup>, Ivanka Marinović<sup>1,2</sup>

<sup>1</sup> Physical Medicine and Rehabilitation with Rheumatology Division, University Hospital of Split, Split, Croatia  
/ Zavod za fizikalnu medicinu i rehabilitaciju s reumatologijom, Klinički bolnički centar Split, Split, Hrvatska

<sup>2</sup> University Department of Health Studies, University of Split, Croatia  
/ Sveučilišni odjel zdravstvenih studija, Sveučilište u Splitu, Hrvatska

<sup>3</sup> Department of Diagnostic and Interventional Radiology, University Hospital of Split, Croatia  
/ Klinički zavod za dijagnostičku i intervencijsku radiologiju, Klinički bolnički centar Split, Split, Hrvatska

<sup>4</sup> School of Medicine, University of Split, Split, Croatia / Medicinski fakultet, Sveučilište u Splitu, Split, Hrvatska

### Corresponding author / Adresa autora za dopisivanje:

Daniela Šošo, MD, PhD

Physical Medicine and Rehabilitation with Rheumatology Division  
/ Zavod za fizikalnu medicinu i rehabilitaciju s reumatologijom  
University Hospital of Split / Klinički bolnički centar Split  
Šoltanska 1  
21000 Split  
Croatia / Hrvatska

Mobile phone number / Mob: 0038521557543

E-mail / e-pošta: soso.daniela@gmail.com

Received / Primljeno: 18<sup>th</sup> October 2023 / 18. 10. 2023.

Accepted / Prihvaćeno: 21<sup>th</sup> December 2023 / 21. 12. 2023.

### ABSTRACT

This is the first case report regarding the co-existence of advanced ankylosing spondylitis (AS) and polymyalgia rheumatica (PMR) in a female patient. So far, it was described in a case series report but exclusively in male patients. A 63-year-old female patient was diagnosed with PMR in 2015, according to EULAR/ACR provisional classification criteria. Glucocorticoid (GC) therapy was successful for all of the symptoms except for the long-lasting pain in the spine. In 2018, additional diagnostic tests were performed. HLA typing showed the presence of HLA-B\*27, radiographs of sacroiliac joints showed grade III bilateral sacroiliitis and MRI described bilateral chronic sacroiliitis with partial ankylosis and subchondral sclerosis of the joints. AS was diagnosed in accordance with the modified New York criteria. Non-steroidal anti-inflammatory (NSAIDs) drugs were used with only small benefits and were discontinued in 2021 due to gastrointestinal complications (development of subileus). In 2021, an MRI of thoracic spine showed signs of anterior spondylitis at the Th5/Th6 level (Romanus lesion) and chronic Romanus lesion at the Th8/Th9 level. Adalimumab was introduced in October of 2021 and reduced symptoms by 60% after four months of treatment, significantly reduced abdominal pain and improved the overall quality of life. Adalimumab had no effect on PMR, but methotrexate and GK were effective in the treatment of PMR.

**KEYWORDS:** ankylosing spondylitis, polymyalgia rheumatica, adalimumab, sacroiliitis

### SAŽETAK

Ovo je prvi prikaz koegzistencije uznapređovaloga ankirozantnog spondilitisa (AS) i reumatske polimijalgije (PMR) u osobe ženskog spola. Do sada je koegzistencija ovih dviju bolesti opisana samo u bolesnika muškog spola. Bolesnica u dobi od 63 godine liječena je od 2015. godine od strane specijalista infektologa pod dijagnozom reumatske polimijalgije (dijagnosticirana prema klasifikacijskim kriterijima EULAR/ACR). Primijenjena glukokortikoidna (GK)

terapija imala je odličan učinak na bol i zakočenost u mišićima. Kako bolesnica cijelo vrijeme ima i perzistentnu bol duž kralježnice koja se ne smanjuje na primijenjenu terapiju, 2018. godine upućena je reumatologu i u daljnju dijagnostičku obradu. HLA tipizacija pokazala je prisutnost HLA-B\*27 alela, radiogram sakroilijakalnih (SI) zglobova prisutnost bilateralnog sakroileitisa trećeg stupnja, a MR SI zglobova bilateralni sakroileitis s parcijalnom ankilozom i subhondralnom sklerozom zglobnih površina. AS je dijagnosticiran prema modificiranim Njujorškim kriterijima. Nesteroidni protuupalni lijekovi (NSAID-ovi), korišteni u početku u punim protuupalnim dozama, polučili su samo blago poboljšanje. Ukinuti su 2021. godine zbog gastrointestinalnih tegoba (razvoj subileusa). Godine 2021. na MR-u torakalne kralježnice opisan je anteriorni spondilitis u razini Th5/Th6 (Romanusova lezija) i kronična Romanusova lezija na razini Th8/Th9. U listopadu 2021. godine započeto je liječenje adalimumabom. Nakon četiri mjeseca bolovi u kralježnici i aktivnost bolesti smanjeni su za oko polovicu, bolesnica više nije imala gastrointestinalnih tegoba, a kvaliteta života joj je poboljšana. Pri pokušaju smanjivanja doze glukokortikoida pojačali su se simptomi reumatske polimialgije na koje adalimumab nema učinak. Dobar učinak na reumatsku polimialgiju ostvaren je kombinacijom metotreksata i glukokortikoida.

**KLJUČNE RIJEČI:** ankilozantni spondilitis, reumatska polimialgija, adalimumab, sakroileitis

## INTRODUCTION

Ankylosing spondylitis (AS) is a part of spondyloarthritides (SpA), a group of chronic inflammatory arthropathies. SpA affects mainly the spine and sacroiliac (SI) joints (axial form of SpA), but also peripheral joints and entheses (peripheral form of SpA) and some extra-articular sites. Ninety-five percent of the white AS population is HLA-B\*27 positive. The estimated worldwide prevalence of AS is between 0.01 and 0.2% [1]. AS is more common in men, with male to female ratio being 2–3:1 [2]. In women, the disease has a later onset, the time period from the onset of symptoms to the diagnosis is longer, and the disease is more often associated with fibromyalgia (FM) [3]. As the disease progresses, irreversible structural changes in the spine and joints occur, which lead to deterioration of the functional status and quality of life in these patients. Although these changes are more pronounced in male patients, it is also known that women who initially have high disease activity measured by the Bath Ankylosing Spondylitis Disease Activity Index (BASDAI) have a more severe form of the disease and a worse treatment outcome [4]. With the introduction of magnetic resonance imaging (MRI), it became possible to diagnose the disease at an early stage, before the occurrence of irreversible changes in the spine and joints. Non-steroidal anti-inflammatory drugs (NSAIDs) are used to treat the axial form of the disease. In case of their ineffectiveness or intolerance, biological therapy is used for treatment, i.e. tumour necrosis factor alpha (TNF- $\alpha$ ) inhibitors, interleukin 17 inhibitors and Janus kinase (JAK) inhibitors. TNF- $\alpha$  inhibitors, especially adalimumab, have been used for the longest time, therefore the experience with the use of this drugs is the greatest.

This case report presents the case of a 63-year-old female who was diagnosed with advanced HLA-B\*27 positive AS and polymyalgia rheumatica (PMR). This is the first described case of the co-existence of these

## UVOD

Ankilozantni spondilitis (AS) dio je spondiloartritisa (SpA), skupine kroničnih upalnih artropatija. SpA zahvaća uglavnom kralježnicu i sakroilijakalne (SI) zglobove (aksijalni oblik SpA), ali također i periferne zglobove i enteze (periferni oblik SpA) i neka izvanzglobna mjesta. Devedeset pet posto populacije bijelaca s AS-om pozitivno je na HLA-B\*27. Procijenjena prevalencija AS-a u svijetu je između 0,01% i 0,02% [1]. AS se češće javlja u muškaraca nego žena, u omjeru 2 – 3:1 [2]. Kod žena bolest počinje kasnije, razdoblje od pojave simptoma do dijagnoze je dulje, a bolest je češće povezana s fibromialgijom (FM) [3]. Kako bolest napreduje dolazi do ireverzibilnih strukturnih promjena u kralježnici i zglobovima, što dovodi do pogoršanja funkcionalnog statusa i kvalitete života ovih bolesnika. Iako su ove promjene izraženije kod muških bolesnika, također je poznato da žene koje u početku imaju visoku aktivnost bolesti mjerenu indeksom aktivnosti bolesti za AS (engl. *Bath Ankylosing Spondylitis Disease Activity Index*, BASDAI) imaju teži oblik bolesti i lošiji ishod liječenja [4]. Uvođenjem magnetske rezonancije (MR) postalo je moguće dijagnosticirati bolest u ranom stadiju, prije nego što nastupe ireverzibilne promjene na kralježnici i zglobovima. Nesteroidni protuupalni lijekovi (NSAID-ovi) upotrebljavaju se za liječenje aksijalnog oblika bolesti. U slučaju njihove neučinkovitosti ili intolerancije na te lijekove, u liječenju se upotrebljava biološka terapija, tj. inhibitori faktora tumorske nekroze alfa (TNF- $\alpha$ ), inhibitori interleukina 17 i inhibitori Janus kinaze (JAK). Inhibitori TNF- $\alpha$ , posebice adalimumab, upotrebljavaju se najdulje, stoga je i iskustvo s primjenom ovih lijekova najveće.

U radu prikazujemo slučaj 63-godišnje bolesnice kojoj je dijagnosticiran uznapredovali ankilozantni spondilitis (AS) s pozitivnim HLA-B\*27 i reumatska polimialgija (PMR). Ovo je prvi opisani slučaj koegzistencije ovih dviju bolesti kod ženske osobe. Do sada je to

two diseases in a female person. So far, it was described in the case report in which the authors express the opinion that shoulder pain is probably part of the clinical features of spondyloarthritis [5]. But, in the case series report, the authors express the opinion that shoulder pain is part of the clinical features of PMR [6]. They believe that in these five patients there is a coexistence of two diseases. In both articles, only male patients were presented. Also, case reports have been published in which patients with late-onset spondyloarthritis were described and their symptoms resembled those of polymyalgia rheumatica [7,8].

In the following part, we will present the course of the patient's illness and the therapeutic dilemmas that arose during the treatment period. This case report will end with a discussion based on the effects of adalimumab in these two diseases.

### CASE REPORT

The first examination of the patient was in 2018 at the Physical Medicine and Rehabilitation with Rheumatology Division, University Hospital of Split. No one in the patient's family suffers from rheumatic diseases, psoriasis or inflammatory bowel disease (IBD). The patient previously suffered from a duodenal ulcer, and she is now being treated for arterial hypertension and her blood count shows an increased number of eosinophils. Over the last ten years, the patient has been experiencing chronic back pain. The back pain was predominantly mechanical in nature. At the beginning of 2015, the diagnosis of spondyloarthritis was ruled out by a rheumatologist but only on the basis of clinical examination. The patient is allergic to diclofenac. Since the end of 2015, the patient was treated for PMR with glucocorticoids (GK) and several NSAIDs as recommended by an infectious disease specialist and a rheumatologist. The reason why the patient was referred to an infectious disease specialist was due to elevated acute phase reactants. PMR was diagnosed in accordance with 2012 EULAR/ACR provisional classification criteria [9]. The patient presented with pain and stiffness of the cervical spine and shoulder girdle muscles, with a slight weakness of the pelvic girdle muscles. Laboratory findings showed elevated acute phase reactants (ESR 46 mm/h, CRP 32 mg/L). The patient had a quick and satisfactory clinical response to a medium dose of GK therapy with a decrease in inflammatory markers. Due to long-lasting pain in the entire spine and limited mobility of the lumbar spine (Schober's test 3,5 cm), additional diagnostic tests were performed in 2018. Laboratory findings showed elevated acute phase reactants again, HLA typing showed the presence of HLA-B\*27 antigen, radiographs of SI joints showed loss of joint space and bilateral partial ankylosis (grade III bilateral sacroiliitis according to the New

opisano u prikazu slučaja u kojem autori iznose mišljenje da je bol u ramenu vjerojatno dio kliničke slike spondiloartritisa [5]. No, u prikazu serije slučajeva, autori izražavaju mišljenje da je bol u ramenu dio kliničke slike reumatske polimijalgije (PMR) [6]. Smatraju da kod ovih pet bolesnika postoji koegzistencija dviju bolesti. U oba članka prikazani su samo muški bolesnici. Također, objavljeni su prikazi slučajeva u kojima su opisani bolesnici s kasnim početkom spondiloartritisa čiji su simptomi nalikovali onima kod reumatske polimijalgije [7,8].

U nastavku ćemo prikazati tijek bolesti bolesnika i terapijske dileme koje su se javljale tijekom razdoblja liječenja. Ovaj prikaz slučaja završit će raspravom o učincima adalimumaba u ove dvije bolesti.

### PRIKAZ BOLESNICE

Prvi pregled bolesnice bio je 2018. u Zavodu za fizikalnu medicinu i rehabilitaciju s reumatologijom KBC-a Split. Nitko u obitelji bolesnice ne boluje od reumatskih bolesti, psorijaze ili upalne bolesti crijeva (engl. *inflammatory bowel disease*, IBD). Bolesnica je ranije bolovala od čira na dvanaesniku, sada se liječi od arterijske hipertenzije, a krvna slika joj pokazuje povećan broj eozinofila. Posljednjih deset godina ima kronične bolove u kralježnici. Bolovi u kralježnici bili su pretežno mehaničke prirode. Početkom 2015. godine reumatolog je odbacio dijagnozu spondiloartritisa, ali samo na temelju kliničkog pregleda. Alergična je na diklofenak. Od kraja 2015. liječena je od PMR-a glukokortikoidima (GK) i raznim NSAID-ovima prema preporuci infektologa i reumatologa. Razlog zbog kojega je bolesnica upućena infektologu bili su visoki reaktanti akutne faze. Reumatska polimijalgija (PMR) dijagnosticirana je pomoću privremenih kriterija klasifikacije EULAR/ACR iz 2012. [9]. Bolesnica je imala bolove i ukočenost mišića vratne kralježnice i ramenog obruča uz blagu slabost mišića zdjeličnog obruča. Laboratorijski nalazi pokazali su povišene reaktante akutne faze (sedimentacija eritrocita [SE] 46 mm/h, C-reaktivni protein [CRP] 32 mg/L). Imala je brz i dobar klinički odgovor na srednju dozu terapije glukokortikoidima (GK) sa smanjenjem upalnih markera. Zbog dugotrajne boli u cijeloj kralježnici i ograničene pokretljivosti lumbalnog dijela kralježnice (Schober test 3,5 cm) učinjene su dodatne dijagnostičke pretrage tijekom 2018. godine. Laboratorijski nalazi opet su pokazali povišene reaktante akutne faze, HLA tipizacija pokazala je prisutnost HLA-B\*27 antigena, radiografije sakroilijakalnih (SI) zglobova pokazale su gubitak zglobnog prostora i bilateralnu parcijalnu ankilozu (III. stupanj bilateralnog sakroileitisa prema Njujorškim kriterijima [NY]: slika 1). Nalaz magnetske rezonancije (MR) opisan je kao bilateralni kronični sakroileitis s parcijalnom ankilozom srednjih dijelova sa subhondralnom

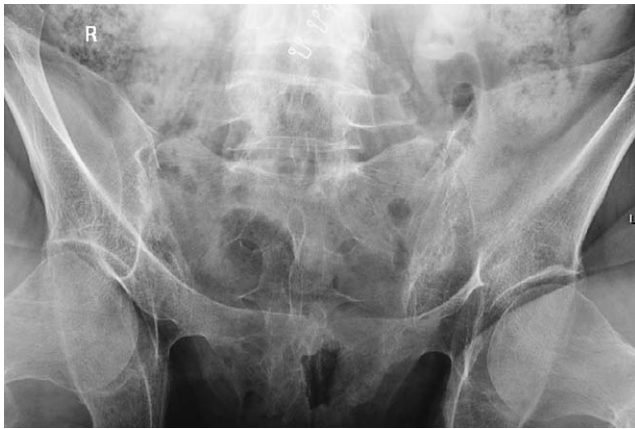

FIGURE 1. Anteroposterior radiograph oblique view of sacroiliac joints showing partial ankylosis of both SI joints defined as grade III sacroiliitis by the New York criteria

SLIKA 1. Rendgenska snimka sakroilijakalnih zglobova po Barshonyju pokazuje parcijalnu ankilozu obaju sakroilijakalnih zglobova koja odgovara trećem stupnju upale prema Njujorškim kriterijima

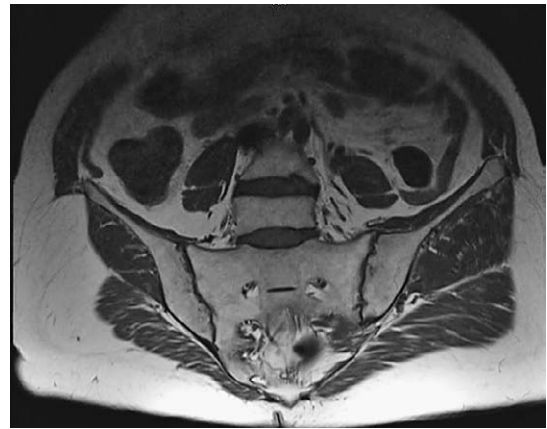

FIGURE 2. MRI of sacroiliac joints – coronal T1 weighted image illustrates narrowing of joint space with partial ankylosis and periarticular fat metaplasia

SLIKA 2. MR sakroilijakalnih zglobova po protokolu za spondiloartritise – koronalna T1 snimka opisuje suženje zglobnih prostora s parcijalnom ankilozom i periartikularnom masnom metaplazijom

York criteria – Figure 1). An MRI revealed signs of bilateral chronic sacroiliitis with partial ankylosis of the middle parts with subchondral sclerosis of the cranial and caudal parts of the joints (Figure 2). Linear subchondral bone marrow oedema was detected in the caudal part of the right SI joint. Only small effusion was detected in both joints. Fibromyalgia (FM), which is diagnosed primarily based on the symptoms, medical history and physical exam, was excluded. AS was diagnosed in accordance with the modified New York criteria (1994) and NSAIDs in full anti-inflammatory doses along with GK and proton pump inhibitors were introduced into the treatment with a moderate effect.

Due to constantly elevated acute phase reactants and persistent back pain, in 2019, bone scintigraphy was also performed. Apart from already known diagnoses, no other cause of the mentioned complaints was found in the case of this patient. Despite medication and regular physical therapy, spinal pain, especially in the cervicothoracic and thoracolumbar areas, was constantly present. This pain prevented the patient from performing work and carrying out daily activities. Therefore, the patient requested a change of workplace first and, following that, she took an early retirement.

In August 2020, the patient developed sudden abdominal pain. MSCT of the abdomen was performed and due to the suspicion that the patient had developed obstructive ileus, she was treated operatively at the Department for Abdominal Surgery. No cause of ileus was found during the operation. An appendectomy was performed, and the tissue of the appendix was found to be normal according to the pathohistological findings. The patient was diagnosed with subileus of unknown cause. At that time, the patient was being treated for AS and PMR with the combination of meloxicam and

sklerozom kranijalnih i kaudalnih dijelova zglobova (slika 2). Linearni edem subhondralne kosti uočen je u kaudalnom dijelu desnog SI zgloba. Primijećen je samo mali izljev u oba zgloba. Fibromialgija (FM), koja se dijagnosticira prvenstveno na temelju simptoma, povijesti bolesti i fizikalnog pregleda, bila je isključena. Ankilozantni spondilitis (AS) dijagnosticiran je u skladu s modificiranim Njujorškim kriterijima (mNY) (1994.) te su u liječenje uvedeni NSAID-ovi u punim protuupalnim dozama uz GK i inhibitore protonske pumpe s umjerenim učinkom.

Zbog konstantno povišenih reaktanata akutne faze i stalnih bolova u kralježnici, 2019. godine učinjena je i scintigrafija kostiju. Osim već poznatih dijagnoza, kod bolesnice nije pronađen nijedan drugi uzrok navedenih tegoba. Unatoč lijekovima i redovitoj fizikalnoj terapiji, bolovi u kralježnici, osobito u cervikotorakalnom i torakolumbalnom području, bili su stalno prisutni. Bolovi su je ograničavali u obavljanju poslova i svakodnevnim aktivnostima. Stoga je prvo tražila promjenu radnog mjesta, a potom otišla u prijevremenu mirovinu.

U kolovožu 2020. počela je osjećati iznenadne bolove u truhu. Učinjen je MSCT abdomena, a zbog sumnje da je bolesnica razvila opstruktivni ileus, operativno je zbrinuta u Zavodu za abdominalnu kirurgiju. Tijekom operacije nije pronađen uzrok ileusa. Učinjena je apendektomija, a tkivo slijepog crijeva je prema patohistološkom nalazu normalno. Bolesnici je dijagnosticiran subileus nepoznatog uzroka. U to vrijeme bila je liječena meloksikamom i metilprednizolonom u dozi od 6 mg zbog ankilozantnog spondilitisa (AS) i reumatske polimialgije (PMR). Kada je MSCT abdomena kasnije analiziran od strane tima reumatologa i radiologa, uočene su promjene koje potvrđuju AS na sakroilijakalnim zglobovima (slika 3).

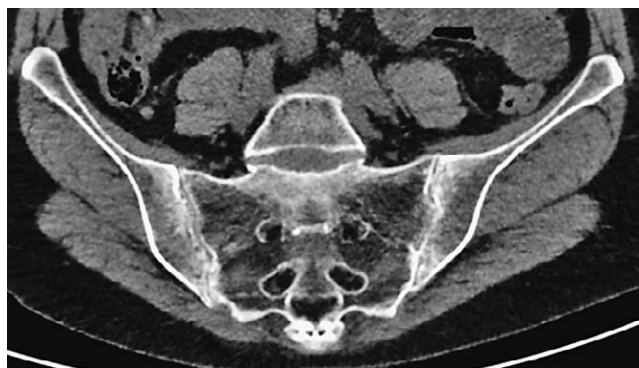

FIGURE 3. Abdominal CT – coronal MPR image showing bilateral grade III sacroiliitis with joint space narrowing, sclerosis and both sacral and iliac bone erosions

SLIKA 3. MSCT abdomena u koronalnom MPR prikazu opisuje, kao usputni nalaz, obostrani sakroileitis trećeg stupnja sa suženjem zglobnog prostora, sklerozacijom zglobnih površina te erozijama na ilijakalnoj i sakralnoj strani zglobova

methylprednisolone in a dose of 6 mg. When the MSCT of the abdomen was later analysed by a team of rheumatologists and radiologists, changes that confirmed the diagnosis of AS were observed on sacroiliac joints (Figure 3).

In September 2020, the patient developed abdominal pain once again due to subileus. The finding of MSCT of the abdomen was very similar to the previous one, the calprotectin level was 648  $\mu\text{g/g}$  (normal values are  $<50 \mu\text{g/g}$ ) and small bowel follow-through findings were normal. The patient continued to take meloxicam and methylprednisolone as this combination of drugs is the most effective for the symptoms of AS and PMR.

In October 2020, she was hospitalized once again and treated for the same reasons, but this time the calprotectin values were significantly lower (68  $\mu\text{g/g}$ ). Antibodies for celiac disease and MR enterography were also performed, and all findings were normal. The patient was then referred to another hospital where a capsule endoscopy was performed. During this procedure, the capsule endoscopy camera was retained in her small intestine. The patient underwent surgery and 7.5 cm of her small intestine was removed. Pathohistological findings were described as normal.

In April 2021, after the patient underwent gastroscopy, colonoscopy and small bowel follow-through, she was treated by a gastroenterologist due to sideropenic anemia. NSAIDs and GK were excluded from therapy by a gastroenterologist and the patient was advised to use only paracetamol. The patient was also recommended to undergo an MR enteroclysis and a colonoscopy with biopsy.

In August 2021, additional exacerbation of inflammatory back pain was observed. The pain level was 9/10 according to the Visual Analogue Scale (VAS), and the acute phase reactants were elevated (ESR 33 mm/h, CRP 28.5 mg/L). The patient was referred for

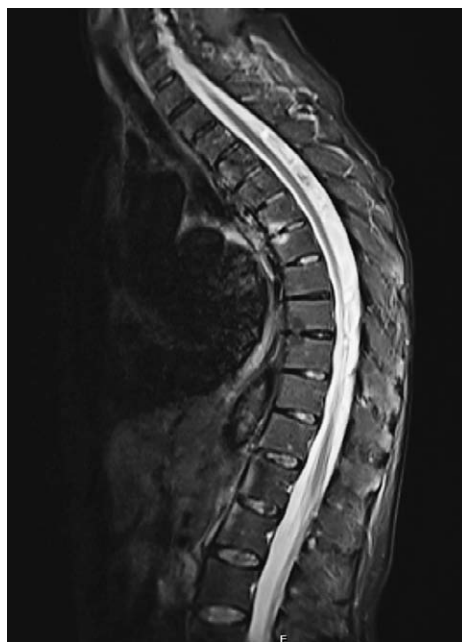


FIGURE 4. MRI of thoracic spine on T2 STIR sagittal sections. Anterior spondylitis of Th5/Th6 level (Romanus lesion), and chronic lesion at the Th8/Th9 level (chronic Romanus lesion)  
SLIKA 4. MR torakalne kralježnice na sagitalnom presjeku T2. Anteriorni spondilitis nivoa Th5/Th6 (Romanusova lezija) te kronična Romanusova lezija na nivou Th8/Th9

U rujnu 2020. ponovno je počela osjećati bolove u trbuhu zbog subileusa. Nalaz MSCT-a abdomena bio je vrlo sličan prethodnom, razina kalprotektina bila je 648  $\mu\text{g/g}$  (normalne vrijednosti su  $<50 \mu\text{g/g}$ ), a pasaža tankog crijeva uredna. Nastavlja uzimati meloksikam i metilprednizolon jer je ova kombinacija lijekova najučinkovitija za simptome ankilozantnog spondilitisa (AS) i reumatske polimialgije (PMR).

U listopadu 2020. ponovno je hospitalizirana i liječena iz istih razloga, ali ovoga puta vrijednosti kalprotektina bile su znatno niže (68  $\mu\text{g/g}$ ). Učinjen je i test antitijela na celijakiju te MR enterografija, svi nalazi bili su uredni. Bolesnica se zatim upućuje u drugu bolnicu u kojoj je obavljena kapsulna endoskopija. Tijekom ovog postupka, kapsulna endoskopska kamera zadržana je u tankom crijevu bolesnice. Bolesnica je operirana te joj je odstranjeno 7,5 cm tankog crijeva. Patohistološki nalaz opisan je kao uredan.

U travnju 2021., nakon gastrokopije, kolonoskopije i pasaže tankog crijeva, liječena je kod gastroenterologa zbog sideropenične anemije. Gastroenterolog je iz terapije isključio nesteroidne protuupalne lijekove (NSAID) i glukokortikoide (GK) te joj je savjetovao da uzima samo paracetamol. Bolesnici je također preporučeno da učini MR enterokliznu i kolonoskopiju s biopsijom.

U kolovozu 2021. primijećeno je dodatno pogoršanje upalne boli u leđima. Razina boli bila je 9/10 prema vizualno-analognj ljestvici (engl. *Visual Analogue*

an MRI of the thoraco-lumbar spine according to the spondyloarthritis protocol. The findings of the MRI of the thoracic spine showed the presence of anterior spondylitis at the Th5/Th6 level (Romanus lesion), and chronic lesion in the front ends of the vertebral bodies at the Th8/Th9 level (chronic Romanus lesion) as seen in Figure 4. The patient also underwent an MR enteroclysis and a colonoscopy with biopsy in September 2021. MR enteroclysis showed a 3 cm long narrowing of the preterminal ileum. Synovitis of the right hip joint and sacroiliitis of the right SI (subchondral oedema of the sacrum) joint were also observed as incidental findings. The pathohistological findings of the biopsy of the terminal ileum showed a normal histological architecture with mononuclear and secondary follicles of medium density in the lamina propria.

In the meantime, the patient started taking methylprednisolone again (on her own accord) in a dose of 4 mg due to the exacerbation of the PMR symptoms.

Due to high disease activity of AS measured by the BASDAI questionnaire (9.6), severe pain measured by VAS (9/10) and morning stiffness lasting longer than two hours, our rheumatology team decided to start the treatment of AS with adalimumab.

We decided to introduce adalimumab into the therapy because of its proven effectiveness in the treatment of AS, as well as in the treatment of inflammatory bowel disease. Laboratory findings showed increased inflammatory markers and the anaemia of chronic disease again.

Treatment with adalimumab began in October 2021. The patient received 40 mg of the drug subcutaneously every 2 weeks. After the third dose of the drug, the patient already felt better. The pain and stiffness were significantly less intense and shorter in duration, but the mobility of the lumbar part of the spine remained the same. The Schober's mobility index was 3.5 cm, same as before the introduction of adalimumab into treatment. Since the patient felt better, she decided to stop taking methylprednisolone. Very quickly, her pain and stiffness in the shoulder girdle muscles got worse and there was an increase in the inflammatory markers. Methylprednisolone in a dose of 6 mg was reintroduced to therapy. Additionally, we introduced methotrexate (MTX) in a dose of 10 mg once a week as a GK-sparing agent but also with the aim of reducing the immunogenicity of adalimumab. GK and MTX significantly reduced the symptoms of PMR.

We evaluated the effectiveness of adalimumab treatment of AS in February 2022, four months after the introduction of the drug. Disease activity and pain level were lower (BASDAI 5.2; VAS 4/10) and morning stiffness was shorter than before, lasting up to one hour.

Abdominal pains no longer occurred. Reactants of the acute phase were lower (ESR 16 mm/h, CRP 21.0

Scale, VAS), a reaktanti akutne faze bili su povišeni (sedimentacija eritrocita [SE] 33 mm/h, C-reaktivni protein [CRP] 28,5 mg/L). Bolesnica je upućena na MR torakolumbalne kralježnice prema protokolu za spondiloartritis. Nalazi magnetske rezonancije (MR) torakalne kralježnice pokazali su prisutnost prednjeg spondilitisa na razini Th5/Th6 (Romanus lezija), te kronične lezije u prednjim krajevima tijela kralješaka na razini Th8/Th9 (kronična Romanus lezija) što je vidljivo na slici 4. Bolesnica je također podvrgnuta MR enteroklizi i kolonoskopiji s biopsijom u rujnu 2021. godine. MR enterokliza pokazala je suženje preterminalnog ileuma u dužini od 3 cm. Sinovitis desnog zgloba kuka i sakroileitis desnog SI (edem subhondralne krstačne kosti) zgloba također su opisani kao slučajni nalazi. Patohistološki nalaz biopsije terminalnog ileuma pokazao je normalnu histološku arhitekturu s mononuklearima srednje gustoće i sekundarnim folikulima u lamini propriji.

U međuvremenu je bolesnica vlastitom odlukom ponovno počela uzimati metilprednizolon u dozi od 4 mg zbog pogoršanja simptoma reumatske polimialgije (PMR).

Zbog visoke aktivnosti bolesti ankilozantnog spondilitisa (AS) mjerene indeksom aktivnosti bolesti za AS (engl. *Bath Ankylosing Spondylitis Disease Activity Index*, BASDAI) (9,6), jake boli mjerene vizualno-analognom ljestvicom (VAS) (9/10) i jutarnje ukočenosti koja traje dulje od dva sata, naš reumatološki tim odlučio je započeti liječenje ankilozantnog spondilitisa (AS) adalimumabom.

Adalimumab smo odlučili uvesti u terapiju zbog njegove dokazane učinkovitosti u liječenju AS-a, kao i u liječenju upalnih bolesti crijeva. Laboratorijski nalazi opet su pokazali povišene upalne markere i anemiju kroničnih bolesti.

Liječenje adalimumabom počelo je u listopadu 2021. godine. Bolesnica je dobivala 40 mg lijeka supkutano svaka dva tjedna. Nakon treće doze lijeka već se osjećala bolje. Bolovi i ukočenost bili su znatno manjeg intenziteta i trajanja, ali je pokretljivost lumbalnog dijela kralježnice ostala ista. Schoberov indeks pokretljivosti bio je 3,5 cm, kao i prije uvođenja adalimumaba. Budući da se osjećala bolje, odlučila je prestati uzimati metilprednizolon. Vrlo brzo pogoršali su se bolovi i ukočenost mišića ramenog obruča i došlo je do porasta upalnih markera. U terapiju je vraćen metilprednizolon u dozi od 6 mg. Dodatno, uveli smo metotreksat (MTX) u dozi od 10 mg jednom tjedno kao sredstvo koje šteti glukokortikoide (GK), ali i s ciljem smanjenja imunogenosti adalimumaba. Glukokortikoidi (GK) i metotreksat (MTX) značajno su smanjili simptome reumatske polimialgije (PMR).

Učinkovitost liječenja ankilozantnog spondilitisa (AS) adalimumabom procijenili smo u veljači 2022., če-

mg/L), and anaemia of chronic disease was no longer found.

## DISCUSSION

In the discussion, we will try to answer these three questions:

1. Is it reasonable to treat a 60-year-old patient with an advanced form of AS and partial ankylosis of the SI joints with a biologic drug?
2. Was adalimumab the best choice for the treatment of this patient?
3. Why didn't we observe a drastically positive effect of adalimumab in the treatment of AS like it was observed in some other diseases?

Answers to these questions are as follows.

Ad 1. We believe that it was reasonable to introduce adalimumab into the treatment despite the partial ankylosis of the SI joints, considering that acute lesions of the thoracic spine are still visible on MRI findings and that this patient still experiences pronounced inflammatory back pain. A good treatment effect and good safety profile of adalimumab is found even in patients with advanced AS and complete spinal ankylosis who still complain of stiffness and inflammatory back pain. Such results were described both on the national level and internationally [10, 11].

Ad 2. Adalimumab has a proven effectiveness in the treatment of both AS and inflammatory bowel disease. Although this patient, despite experiencing abdominal pain and occasionally increased levels of calprotectin in her stool (the patient was then treated with meloxicam), did not have a diagnosis of inflammatory bowel disease, gastrointestinal complaints decreased and the patient was not treated in the hospital again after the introduction of adalimumab into therapy. On the other hand, TNF- $\alpha$  inhibitors have no effect in the treatment of PMR [12]. Some studies showed that the IL-6 inhibitor, tocilizumab, can be effective in the treatment of resistant PMR [13] but tocilizumab has no effect in the treatment of AS. Therefore, we believe that adalimumab, combined with GK and MTX in the treatment of PMR, is the best choice for the treatment of AS in the case of this patient.

Ad 3. Although significant improvement was achieved with the introduction of adalimumab into therapy, this patient still experiences morning stiffness of the spine that lasts for about an hour and disease activity with a BASDAI score above 5. The moderate effect of adalimumab can be explained by a high initial index of disease activity (BASDAI 9.6), as previously described in literature [4].

## CONCLUSION

This is the first described case of advanced AS and PMR in a female patient. NSAIDs did not have a satis-

tiri mjeseca nakon uvođenja lijeka. Aktivnost bolesti i razina boli bili su niži (BASDAI 5,2; VAS 4/10), a jutarnja ukočenost bila je kraća i trajala je do sat vremena.

Više se ne javljaju bolovi u abdomenu. Reaktanti akutne faze su niži (sedimentacija eritrocita [SE] 16 mm/h, C-reaktivni protein [CRP] 21,0 mg/L), nema više anemije kronične bolesti.

## RASPRAVA

U raspravi ćemo pokušati odgovoriti na ova tri pitanja:

1. Je li razumno bolesnicu od 60 godina s uznapređovalim oblikom ankilozantnog spondilitisa (AS) i djelomičnom ankilozom sakroilijalnih (SI) zglobova liječiti biološkim lijekom?
2. Je li adalimumab bio najbolji izbor za liječenje ove bolesnice?
3. Zašto nije vidljiv drastično dobar učinak adalimumaba u liječenju ankilozantnog spondilitisa (AS) kao kod nekih drugih bolesti?

Odgovori na ova pitanja navedeni su u nastavku.

Odg. 1. Smatramo da je bilo razumno uvesti adalimumab u liječenje unatoč djelomičnoj ankilozu sakroilijalnih (SI) zglobova, s obzirom na to da su akutne lezije torakalne kralježnice i dalje vidljive na nalazima MR-a te da ova bolesnica još uvijek ima izraženu upalnu bol u kralježnici. Dobar učinak liječenja i dobar sigurnosni profil adalimumaba utvrđen je čak i kod bolesnika s uznapređovalim AS-om i potpunom spinalnom ankilozom koji se i dalje žale na ukočenost i upalnu bol u kralježnici. Takvi rezultati opisani su i na nacionalnoj razini i u inozemstvu [10, 11].

Odg. 2. Adalimumab je dokazano učinkovit u liječenju AS-a i upalne bolesti crijeva. Iako ova bolesnica, unatoč bolovima u truhu i povremeno povišenim razinama kalprotektina u stolici (bolesnica je tada liječena meloksikamom), nije imala dokazanu upalnu bolest crijeva, gastrointestinalne tegobe su se smanjile, a bolesnica nije niti jednom bolnički liječena nakon uvođenja adalimumaba. S druge strane, inhibitori TNF- $\alpha$  nemaju učinka u liječenju reumatske polimialgije (PMR) [12]. Neka su istraživanja pokazala da inhibitor IL-6, tocilizumab može biti učinkovit u liječenju rezistentne reumatske polimialgije (PMR) [13], ali tocilizumab nema učinka u liječenju ankilozantnog spondilitisa (AS). Stoga smatramo da je adalimumab, u kombinaciji s glukokortikoidima (GK) i metotreksatom (MTX) u liječenju reumatske polimialgije (PMR), najbolji izbor za liječenje ankilozantnog spondilitisa (AS) u slučaju ove bolesnice.

Odg. 3. Iako smo postigli značajno poboljšanje u liječenju adalimumabom, ova bolesnica još uvijek ima jutarnju ukočenost kralježnice koja traje oko sat vremena i aktivnost bolesti s BASDAI indeksom iznad 5. Umjereni učinak adalimumaba može se objasniti viso-

factory effect on the treatment of AS in our patient. After only four months of treatment, adalimumab reduced pain measured through VAS pain scoring and disease activity measured through BASDAI by about half. Also, according to the patient's own opinion, it significantly reduced abdominal pain and improved her overall quality of life. As expected, adalimumab had no effect on PMR, but MTX and GK were effective in the treatment of PMR.

**AUTHOR CONTRIBUTIONS:** Conceptualization, J.A. and D.Š.; writing – original draft preparation, J.A., D.Š.; writing – review and editing I.M. and D.M.K.; data analyses S.L.K. All authors have read and agreed to the published version of the manuscript.

**ACKNOWLEDGMENTS:** The authors report no acknowledgments.

**FUNDING:** For this work authors did not receive any funding.

**INFORMED CONSENT STATEMENT:** Written informed consent was obtained from the patient.

**CONFLICT OF INTEREST STATEMENT:** JA, IM and DŠ report that they have received a fee from Fresenius Kabi. SLK, KD and DMK declare no conflict of interest. Some parts of this case report were reported in the Kabi-Care journal (and they were written in the Croatian language) which is intended only for medical professionals in Croatia with prior registration and password protection. A written permission was obtained from Fresenius Kabi to use parts of this professional paper in this scientific paper.

kim početnim indeksom aktivnosti bolesti (BASDAI 9,6), kako je prethodno opisano u literaturi [4].

## ZAKLJUČAK

Ovo je prvi opisani slučaj uznappedovaloga ankilozantnog spondilitisa (AS) i reumatske polimialgije (PMR) kod osobe ženskog spola. Nesteroidni protuupalni lijekovi (NSAID) nisu imali zadovoljavajući učinak na liječenje ankilozantnog spondilitisa (AS) u slučaju naše bolesnice. Nakon samo četiri mjeseca liječenja, adalimumab je otprilike upola smanjio rezultate intenziteta boli mjerene vizualno-analognom ljestvicom (VAS) i aktivnost bolesti mjerenu BASDAI indeksom. Bolesnica je, prema vlastitom mišljenju, primijetila i značajno manju bol u abdomenu i bolju kvalitetu života. Očekivano, adalimumab nije imao učinak na reumatsku polimialgiju (PMR), ali metotreksat (MTX) i glukokortikoidi (GK) su bili učinkoviti u njezinom liječenju.

**DOPRINOSI AUTORA:** Konceptualizacija: J.A. i D.Š.; pisanje – priprema izvorne radne verzije teksta: J.A. i D.Š.; pisanje – pregled i redakcija teksta: I.M. i D.M.K.; analize podataka: S.L.K. Svi su autori pročitali rukopis i složili se s objavljenom verzijom rukopisa.

**ZAHVALA:** Autori nisu naveli zahvale za ovaj rad.

**FINANCIRANJE:** Autori za ovaj rad nisu primili nikakva sredstva.

**IZJAVA O INFORMIRANOM PRISTANKU:** Od bolesnice je dobivena izjava o informiranom pristanku u pisanom obliku.

**IZJAVA O SUKOBU INTERESA:** JA, IM i DŠ prijavljuju naknade dobivene od tvrtke Fresenius Kabi. SLK, KD i DMK izjavljuju da nisu u sukobu interesa. Određeni dijelovi ovog prikaza bolesnice objavljeni su u časopisu *Kabi-Care* na hrvatskom jeziku koji je namijenjen samo zdravstvenim djelatnicima u Hrvatskoj uz prethodnu registraciju i zaštitu lozinkom. Od tvrtke Fresenius Kabi dobiveno je pisano dopuštenje za korištenje dijelova ovoga stručnog rada u ovom znanstvenom radu.



## REFERENCES / LITERATURA

1. Siebert S, Raj S, Tsoukas A. The epidemiology of ankylosing spondylitis, axial spondyloarthritis, and back pain. In: Siebert S, Sengupta R, Tsoukas A, editors. *Axial Spondyloarthritis*. New York: Oxford University Press; 2016.
2. Will R, Edmunds L, Elsworth J, Calin A. Is there sexual inequality in ankylosing spondylitis? A study of 498 women and 1202 men. *J Rheumatol*. 1990;17(12):1649-52.
3. Slobodin G, Reyhan I, Avshovich N, Balbir-Gurman A, Boulman N, Elias M et al. Recently diagnosed axial spondyloarthritis: gender differences and factors related to delay in diagnosis. *Clin Rheumatol*. 2011;30(8):1075-80.
4. Roussou E, Sultana S. Spondyloarthritis in women: differences in disease onset, clinical presentation, and Bath Ankylosing Spondylitis Disease Activity and Functional indices (BASDAI and BASFI) between men and women with spondyloarthritis. *Clin Rheumatol*. 2011;30(1):121-7.
5. Aydeniz A, Akaltun MS, Gur A, Gursoy S. Coexistence of polymyalgia rheumatica with ankylosing spondylitis: A case report. *Agri*. 2018;30(1):35-7.
6. Elkayam O, Paran D, Yaron M, Caspi D. Polymyalgia rheumatica in patients with ankylosing spondylitis: a report of 5 cases. *Clin Exp Rheumatol*. 1997;15(4):411-4.
7. Aydeniz A, Altindag O, Ogut E, Gursoy S. Late onset spondyloarthropathy mimicking polymyalgia rheumatica. *Rheumatol Int*. 2012;32(5):1357-8.
8. Olivieri I, Garcia-Porrua C, Padula A, Cantini F, Salvarani C, Gonzalez-Gay MA. Late onset undifferentiated spondyloarthritis presenting with polymyalgia rheumatica features: description of seven cases. *Rheumatol Int*. 2007;27(10):927-33.
9. Dasgupta B, Cimmino MA, Kremers HM, Schmidt WA, Schirmer M, Salvarani C et al. 2012 Provisional classification criteria for polymyalgia rheumatica: a European League Against Rheumatism/American College of Rheumatology collaborative initiative. *Arthritis Rheum*. 2012;64(4):943-54.
10. Grubisic F, Naglic DB, Peric P, Morovic-Vergles J, Anic B, Kehler T et al. Clinical efficacy and safety of adalimumab versus etanercept in patients with ankylosing spondylitis and total spinal ankylosis in Croatia: a multicentre 12-month follow-up study. *Clin Rheumatol*. 2022;41(8):2417-21.
11. van der Heijde D, Pangan AL, Schiff MH, Braun J, Borofsky M, Torre J et al. Adalimumab effectively reduces the signs and symptoms of active ankylosing spondylitis in patients with total spinal ankylosis. *Ann Rheum Dis*. 2008;67(9):1218-21.
12. Mahmood SB, Nelson E, Padniewski J, Nasr R. Polymyalgia rheumatica: An updated review. *Cleveland Clin J Med*. 2020;87(9):549-56.
13. Farinango M, Ansary A, Dakka A, Nazir Z, Shamim H, Jean M, et al. Is Tocilizumab effective and safe in polymyalgia rheumatica and giant-cell arteritis with polymyalgia rheumatica? *Cureus*. 2022;14(8):e27606.