

## CHALLENGES IN THE TREATMENT OF NEURO-BEHÇET'S DISEASE — A CASE REPORT

### IZAZOVI U TRETMANU NEURO-BEHÇETOVE BOLESTI – PRIKAZ BOLESNIKA

Samir Mehmedagić<sup>1</sup>, Nejra Džananović<sup>2</sup>

<sup>1</sup> Clinic for Heart, Blood Vessel and Rheumatic Diseases, Clinical Center University of Sarajevo, Sarajevo, Bosnia and Herzegovina  
/ Klinika za bolesti srca, krvnih žila i reumatizam, Univerzitetski klinički centar Sarajevo, Sarajevo, Bosna i Hercegovina

<sup>2</sup> Department of Clinical Biochemistry and Immunology, Clinical Center University of Sarajevo, Sarajevo, Bosnia and Herzegovina  
/ Klinika za biohemiju i imunologiju, Univerzitetski klinički centar Sarajevo, Sarajevo, Bosna i Hercegovina

#### Corresponding author / Adresa autora za dopisivanje:

Samir Mehmedagić, MD

Clinic for Heart, Blood Vessel and Rheumatic Diseases / Klinika za bolesti srca, krvnih žila i reumatizam  
Clinical Center University of Sarajevo / Univerzitetski klinički centar Sarajevo

Bolnička ul. 25

71000 Sarajevo

Bosnia and Herzegovina / Bosna i Hercegovina

E-mail / E-pošta: samir.mehmedagic@bih.net.ba

Received / Primljeno: 1<sup>st</sup> June 2022 / 1. 6. 2022.

Accepted / Prihvaćeno: 25<sup>th</sup> September 2022 / 25. 9. 2022

#### ABSTRACT

Behçet's disease is a multisystem disease of insufficiently known etiology, with genetics playing a significant role in its development, featuring an increased frequency of the HLA-B51 gene in the genome of patients, but it can sometimes also be associated with the presence of certain strains of bacteria. Pathogenetically, this disease is considered to be small-vessel vasculitis. The disease most often manifests itself in oral and genital ulcerations with frequent uveitis and skin changes, and, in very rare cases, there are neurological manifestations, which occur in less than 10 percent of patients that suffer from this disease, and in that case we call it the neuro-Behçet's disease. The treatment of this disease depends on the clinical condition and the treatment approach is individual for each patient. The greatest challenge is the treatment of neuro-Behçet's disease due to the severity of the clinical condition and frequent inadequate response to therapy. Neuro-Behçet's disease is treated with corticosteroids, various immunosuppressants and biological therapy – e.g., TNF-alpha inhibitors as the latest form of therapy with the best results. This paper intends to present the case of a patient with neurological manifestations of the disease, the challenges that we faced during the treatment, the complications that occurred, and the resulting changes in therapy that were sometimes necessary.

**KEY WORDS:** Behçet's disease, etiology, criteria, neuro-Behçet, clinical manifestations, diagnosis, therapy, immunosuppressive, biological therapy, TNF alpha inhibitors

#### SAŽETAK

Behçetova bolest je multisistemska bolest nedovoljno poznate etiologije, no genetika ima značajnu ulogu u njenom nastanku, s većom učestalošću prisutnosti gena HLAB51 u genomu oboljelih, no ponekad se može povezati i s prisutnošću nekih sojeva bakterija. Patogenetski to je vaskulitis malih krvnih žila. Bolest se najčešće manifestira oralnim i genitalnim ulceracijama uz čestu pojavu uveitisa, kožnih promjena, te vrlo rijetku prisutnost neuroloških manifestacija koje se javljaju u manje od 10% pacijenata koji boluju od ove bolesti (nazivamo je neuro-Behçetova bolest). Liječenje ove bolesti ovisi o kliničkoj slici i pristup je individualan za svakog bolesnika, a najveći izazov predstavlja liječenje neuro oblika Behçetove bolesti zbog težine kliničke slike i vrlo često neadekvatnog odgovora na terapiju koja je uključena. Neuro-Behçet se liječi kortikosteroidima, raznim imunosupresivima i biološkom terapijom – TNF alfa inhibitorima kao najnovijom vrstom terapije kojom se postižu najbolji rezultati. U ovome radu želimo prikazati slučaj bolesnika s neurološkim manifestacijama bolesti, izazove koji su nas pratili tijekom liječenja, komplikacije koje su se dogodile, a samim time i promjene u terapiji koje su ponekad bile potrebne.

**KLJUČNE RIJEČI:** Behçetova bolest, etiologija, kriteriji, neuro-Behçet – kliničke manifestacije, dijagnostika, terapija, imunosupresivna, biološka terapija, TNF alfa inhibitori.

## INTRODUCTION

Behçet's disease is a multisystemic, recurrent, inflammatory disorder that affects the mucous membranes, skin, eyes, joints, cardiovascular and gastrointestinal system, lungs, blood vessels, and central and peripheral nervous system, and its pathophysiological basis is small-vessel vasculitis. The changes related to this disease were described by the Turkish dermatologist Hulusi Behçet, and the disease was named after him. (1) The disease is most often manifested by changes in the mucous membranes – oral and genital ulcerations, changes in the skin – erythema nodosum, pseudofolliculitis and joint involvement (in the sense of arthritis) and the eyes – uveitis or retinal vasculitis, as well as the relatively frequent presence of general symptoms: elevated body temperature, fatigue, malaise and weight loss. In addition to oral ulcerations, the criteria for diagnosis are two more signs from the following: genital ulcerations, skin lesions, a positive pathergy test, and eye lesions (2).

The nervous system is affected in up to 10% of patients diagnosed with Behçet's disease. The first autopsy of a patient with neurological manifestations was performed in Berlin in 1944. (1)

The etiology of the disease is still unclear, but the tissue HLA-B51 histocompatibility gene is often present in patients suffering from this disease (2). It is more common in men, and the prevalence is 20–602/100,000 population in Turkey. (3) In rural and urban areas of Turkey, the disease incidence is different depending on the region. In Europe, data indicate a prevalence of 0.64/100,000 population for the United Kingdom, 1.2/100,000 population for Sweden, 1.5/100,000 population for Portugal, 3.7/100,000 population for Italy, 5.6/100,000 population for Spain and 7.2/100,000 population for France. The prevalence for Germany is 1.47/100,000 population, but it is significantly higher if we consider only the immigrants — Turks living in Germany (77/100,000 population). (3,4)

If, in addition to the aforementioned symptoms, there are also signs of nervous system involvement (central or peripheral), we can say that that is the case of neuro-Behçet's disease, which can generally manifest itself in three forms: 1. subacute brainstem involvement with cranial neuropathy, oculomotor abnormalities, nystagmus, paralysis of motion, speech difficulties, ataxia; 2. meningomyelitis with signs of inflammation; 3. confusion syndrome caused by meningoencephalitis initially without focal neurological signs, but with dementia, quadriparesis and pseudobulbar palsy (1). Neuro-Behçet's disease can also be divided into primary when parenchymal brain structures of gray and white matter or nerves are affected, and secondary due to dural venous sinus thrombosis, superior vena cava and increased intracranial pressure, while arterial

## UVOD

Behçetova bolest je multisistemijski, rekurentni, upalni poremećaj koji zahvaća sluznice, kožu, oči, zglobove, kardiovaskularni i gastrointestinalni sustav, pluća, krvne žile te središnji i periferni živčani sustav, a sve na patofiziološkoj osnovi vaskulitisa malih krvnih žila. Promjene je opisao turski dermatolog Hulusi Behçet, po kojemu je bolest i dobila ime. (1). Bolest se najčešće očituje promjenama na sluznicama – oralne i genitalne ulceracije, promjenama na koži – nodozni eritem, pseudofolikulitis i zahvaćenost zglobova u smislu artritisa te očiju – uveitis ili retinalni vaskulitis, kao i relativno česta prisutnost općih simptoma: povišene tjelesne temperature, umora, malaksalosti i gubitka na tjelesnoj težini. Uz oralne afte, kriteriji za dijagnozu su još dva znaka od sljedećih: genitalne afte, kožne lezije, pozitivan patergijski test i lezije oka (2).

Živčani sustav zahvaćen je u do 10% bolesnika s dijagnozom Behçetove bolesti. Prva obdukcija bolesnika s neurološkim manifestacijama obavljena je u Berlinu 1944. godine. (1)

Etiologija bolesti je nedovoljno razjašnjena, ali je često prisutan gen tkivne histokompatibilnosti HLAB51 (2). Češća je u muškaraca, a prevalencija je 20–602/100.000 u Turskoj. (3) U ruralnim i urbanim područjima Turske učestalost je različita ovisno o regiji. U Europi podaci govore o prevalenciji od 0,64/100.000 za Ujedinjeno Kraljevstvo, 1,2/100.000 za Švedsku, 1,5/100.000 za Portugal, 3,7/100.000 za Italiju, 5,6/100.000 za Španjolsku i 7,2/100.000 za Francusku. Prevalencija za Njemačku je 1,47/100.000, ali je značajno viša ako uzmemo u obzir samo imigrante – Turke koji žive u Njemačkoj (77/100.000). (3,4)

Ako uz navedene simptome imamo i znakove zahvaćenosti živčanog sustava (centralnog ili perifernog), možemo reći da se radi o neuro-Behçetovoj bolesti, koja se općenito može manifestirati u tri oblika: 1. subakutno zahvaćanje moždanog debla s kranijalnom neuropatijom, okulomotornim abnormalnostima, nistagmusom, paralizom pokreta, otežanim govorom i ataksijom; 2. meningomijelitis sa znakovima upale; 3. sindrom konfuzije uzrokovan meningoencefalitisom u početku bez žarišnih neuroloških znakova, ali s demencijom, kvadriparezom i pseudobulbarnom paralizom (1). Neuro-Behçet se također može podijeliti na primarni, kada su zahvaćene parenhimske moždane strukture sive i bijele tvari ili živci, te sekundarni zbog tromboze duralnih venskih sinusa, gornje šuplje vene i povišenog intrakranijalnog tlaka, dok je arterijska tromboza rijetka kao i aneurizme, a može se manifestirati i kao kombinirani parenhimski i neparenhimski oblik. Osim središnjega živčanog sustava bolest može zahvatiti i periferni živčani sustav u obliku periferne neuropatije, mononeuritisa multipleksa, mioopatije i miozitisa (1, 5, 6).

thrombosis is as rare as aneurysms, and can also manifest as a combined parenchymal and non-parenchymal form. In addition to the central nervous system, the disease can also affect the peripheral nervous system in the form of peripheral neuropathy, mononeuritis multiplex, myopathy and myositis (1, 5, 6).

In a large study which included 200 patients with Behçet's disease and which was conducted by Akman-Demir et al. 162 of these patients had parenchymal disease, 51% of them had brainstem involvement combined with other parenchymal lesions, 14% of them had spinal involvement, 15% of them had hemispheric involvement, and 19% of them had isolated pyramidal signs. Dural sinus thrombosis and occlusion of the superior vena cava with consequent increased intracranial pressure were present in 34 patients, aseptic meningitis was found in one patient, while occlusion, dissection or aneurysm of blood vessels was present in three patients. (1,6).

The most common changes found through brain MRI are lesions on the brain stem and basal ganglia (5). In these patients, we find elevated levels of protein in the cerebrospinal fluid, while in the group with non-parenchymal changes, we find biochemical analyzes with no abnormalities and increased intracranial pressure. (1,5,6,7)

Symptoms and signs that occur in Neuro-Behçet's disease are: headache, speech difficulties, hemiparesis, ataxia, cognitive disorders and behavioral disorders with vision loss due to optic neuritis or retinal vasculitis, while extrapyramidal disorders are sporadic. For patients who meet the diagnostic criteria for Behçet's disease, other known systemic or neurological diseases with similar symptoms should be excluded. Objective abnormalities consistent with neuro-Behçet's disease are detected either by neurological examination, imaging methods, primarily magnetic resonance imaging (MRI), and based on abnormal cerebrospinal fluid findings. (1,5,7,8).

In the treatment of patients with Behçet's disease, the approach is individual for each patient, depending on the current clinical features, from local therapy of the mucous membrane of aphthous ulcerations to oral systemic therapy or parenteral therapy with corticosteroids and immunosuppressants. The approach is different and variable depending on the course of the disease. In the treatment of neuro-Behçet's disease, glucocorticoids are used initially and during further treatment, depending on the course of the disease, as well as azathioprine, methotrexate, cyclophosphamide, TNF-alpha inhibitors and rituximab (9). Therapeutic success is varied in terms of improvement of clinical condition, remission and disease recurrence. Although changes in therapy are expected, disability and mortality are high with the currently available therapy.

U velikoj studiji od 200 bolesnika s Behçetovom bolešću koju su proveli Akman-Demir i suradnici njih 162 su imala parenhimsku bolest, od čega je njih 51% imalo zahvaćenost moždanog debla u kombinaciji s drugim parenhimskim lezijama, 14% zahvaćenost kralježnice, 15% je uključivalo hemisfere, a 19% bolesnika imalo je izolirane piramidalne znakove. Trombozu duralnih sinusa i okluziju gornje šuplje vene s posljedičnim povišenim intrakranijskim tlakom imalo je 34 bolesnika, aseptični meningitis je nađen u jednog bolesnika, dok je okluzija, disekcija ili aneurizma krvnih žila bila prisutna u tri bolesnika (1,6).

Najčešće promjene koje se nalaze na magnetskoj rezonanciji mozga jesu lezije na moždanom deblu i bazalnim ganglijima (5). U ovih bolesnika nalazimo povišene proteine u cerebrospinalnoj tekućini, dok u skupini neparenhimskih promjena imamo uredne biokemijske analize s povećanim intrakranijalnim tlakom. (1,5,6,7)

Simptomi i znakovi koji se javljaju kod neuro-Behçetove bolesti jesu: glavobolja, otežan govor, hemipareza, ataksija, kognitivni poremećaji i poremećaji ponašanja s gubitkom vida zbog optičkog neuritisa ili vaskulitisa retine, dok su ekstrapiramidalni poremećaji sporadični. Za bolesnike koji zadovoljavaju dijagnostičke kriterije za Behçetovu bolest treba isključiti druge poznate sustavne ili neurološke bolesti sa sličnim simptomima. Objektivne abnormalnosti koje su u skladu s neuro-Behçetovom bolešću otkrivaju se neurološkim pregledom, slikovnim metodama, prvenstveno magnetskom rezonancijom i na temelju abnormalnih nalaza pregleda cerebrospinalne tekućine. (1,5,7,8).

U liječenju bolesnika s Behçetovom bolesti pristup je individualan, ovisno o trenutnoj kliničkoj slici, od lokalne terapije sluznice afti do sistemske terapije *per os* ili parenteralne terapije kortikosteroidima i imunosupresivima. Pristup je različit i varijabilan ovisno o tijeku bolesti. Za neuro oblik Behçetove bolesti koriste se glukokortikoidi u početku i tijekom daljnjeg liječenja, ovisno o tijeku bolesti, te azatioprin, metotreksat, ciklofosfamid, TNF alfa inhibitori i rituksimab (9). Terapijski uspjesi su različiti u pogledu kliničkog poboljšanja, remisije i recidiva bolesti. Iako se očekuju promjene u terapiji, uz sadašnju dostupnu terapiju invaliditet i smrtnost su visoki.

## PRIKAZ BOLESNIKA

Predstavljamo bolesnicu koja je u vrijeme postavljanja dijagnoze imala 27 godina, a prve tegobe u smislu oralnih i genitalnih ulceracija pojavile su se 2019. godine s kožnim promjenama opisanim kao nodozni eritem. Zatim ju je liječio ginekolog i pregledao reumatolog u lokalnoj bolnici, koji je posumnjao na Behçetovu bolest i preporučio prvo parenteralnu terapiju glukokortikoidima, a zatim oralni metil-prednizolon. Bole-

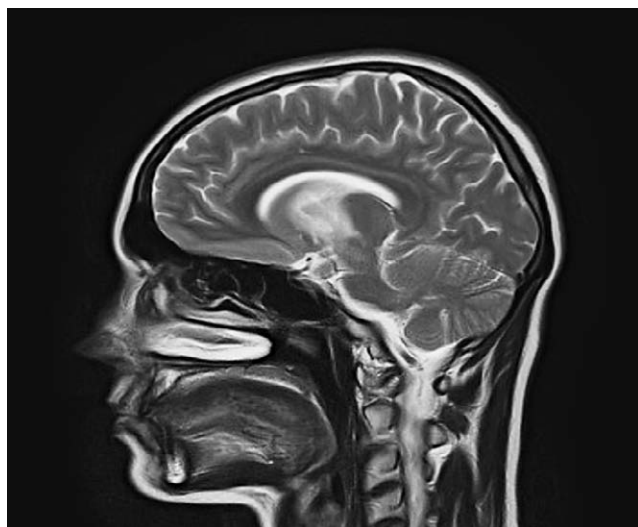


FIGURE 1 MRI of the brain of a patient with Behçet's disease and changes in the area of mesencephalon – the sagittal section

SLIKA 1. Magnetna rezonancija mozga bolesnice s Behçetovom bolesti i promjenama u području mezencefalona – sagitalni presjek

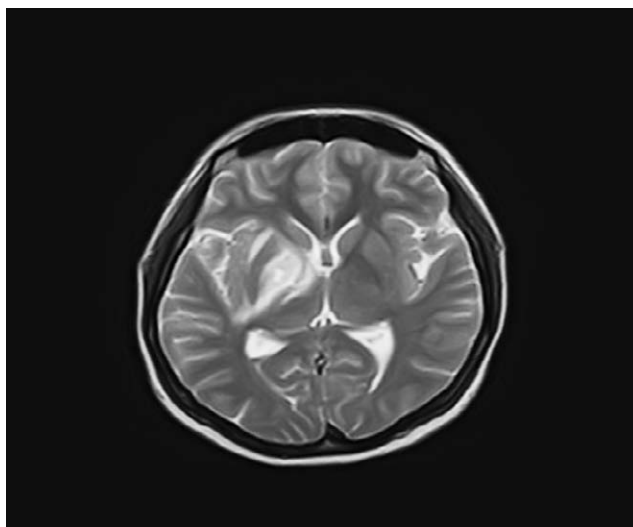


FIGURE 2 Brain MRI — changes in the area of the basal ganglia and mesencephalon – transverse section

SLIKA 2. Magnetna rezonancija mozga – promjene u području bazalnih ganglija i mezencefalona – transverzalni presjek

### CASE REPORT

We present the case of a patient who was 27 years old at the time of diagnosis, and the first difficulties appeared in the form of oral and genital ulcerations in 2019, with skin changes described as erythema nodosum. The patient was then treated by a gynecologist and examined by a rheumatologist at a local hospital, who suspected that this was the case of Behçet's disease and recommended to start using parenteral glucocorticoid therapy followed by methylprednisolone administered orally. The patient did not adhere to the recommended therapy nor did she show up to follow-up examinations. In the spring of 2020, she began to experience intense headaches along with elevated body temperature and mild left-sided hemiparesis. She was processed again at the local hospital and further processing was recommended at our clinical center at the Neurology Clinic. During the patient's hospitalization period at the Neurology Clinic, various examinations were performed, including brain MRI, which showed changes in the area of the basal ganglia and mesencephalon with an increased signal in the T2 and FLAIR sequences, with slight compression on the right lateral ventricle. The neuroradiologist associated these findings with Behçet's disease (Figures 1 and 2).

A rheumatologist was then consulted on the matter, who recommended further treatment at the Rheumatology Department of the Clinic for Heart, Blood Vessel and Rheumatic Diseases, at the end of June 2020. Additional tests were performed, and elevated ESR and CRP values were found, as well as negative immunological tests for systemic connective tissue diseases and

snica se nije pridržavala preporučene terapije niti dolazila na kontrolne preglede. U proljeće 2020. počele su se javljati intenzivne glavobolje uz povišenu tjelesnu temperaturu i blagu lijevostranu hemiparezu. Ponovno je obrađena u lokalnoj bolnici i preporučena je daljnja obrada u našem kliničkom centru u neurološkoj klinici. Tijekom hospitalizacije na neurološkoj klinici obavljene su pretrage, uključujući MR mozga, koji je pokazao promjene u području bazalnih ganglija i mezencefalona s pojačanim signalom u sekvencama T2 i FLAIR, koje se ponašaju blago kompresivno na desnu lateralnu komoru, što je neuroradiolog povezoao s Behçetovom bolešću (slike 1 i 2).

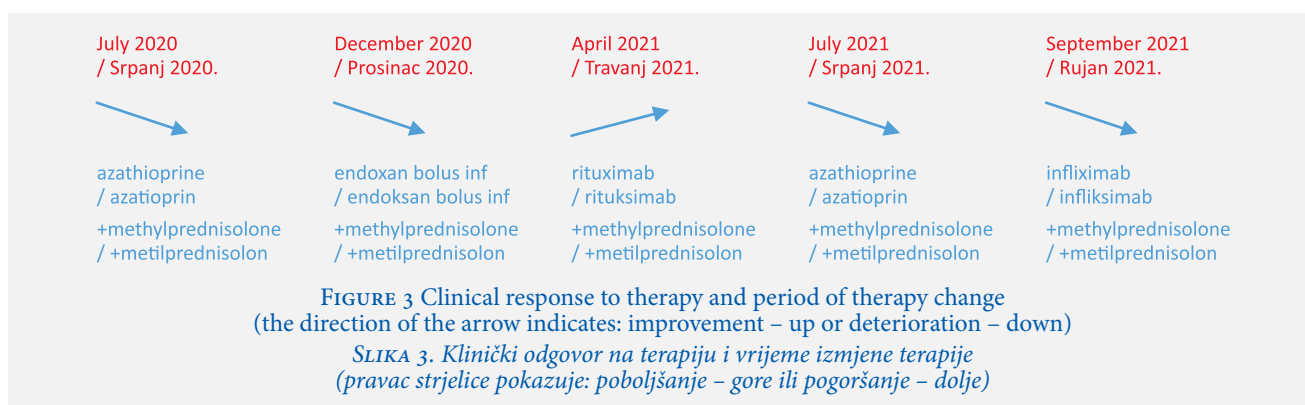Potom je konzultiran reumatolog koji je preporučio daljnje liječenje na reumatološkom odjelu Klinike za bolesti srca, krvnih žila i reumatizam, krajem lipnja 2020. godine. Učinjene su dodatne pretrage, a nađene su povišene vrijednosti SE i CRP, negativne imunološke pretrage u smjeru sistemskih bolesti vezivnog tkiva i drugih vaskulitisa (anti-CCP, ANA, anti ds DNA, p i c ANCA), uz pozitivan HLA B51 lokus. Na temelju svih učinjenih pretraga te ranijih promjena na koži i trenutnih promjena na sluznicama postavlja se dijagnoza Behçetove bolesti, odnosno neuro-Behçetove bolesti, s obzirom na prisutnu simptomatologiju i promjene na MR-u mozga. U terapiju se uključi metil-prednizolon 32 mg i azatioprin 2 x 50 mg te se bolesnica otpušta iz bolnice, uz preporuku nastavka preporučene terapije. S obzirom na udaljenost mjesta stanovanja od našega kliničkog centra, tada se nismo odlučili za terapiju ciklofosamidom, uz mogućnost naknadnog uključivanja u terapiju ako ne bude odgovora na preporučenu

other types of vasculitis (anti-CCP, ANA, anti-dsDNA, P-ANCA and C-ANCA), along with a positive HLA-B51 locus. On the basis of all tests performed and earlier changes on the skin and current changes on the mucous membranes, a diagnosis of Behçet's disease, or neuro-Behçet's disease, was established, taking into account the current symptoms and changes found on brain MRI. Methylprednisolone in the dose of 32 mg and azathioprine in the dose of 2 x 50 mg were included in the therapy, and the patient was discharged from the hospital, with the recommendation to continue the recommended therapy. Considering the distance of the patient's address of residence from our clinical center, we opted not to use the cyclophosphamide therapy at that time, with the possibility of subsequent inclusion in the therapy if there was no response to the recommended therapy. The patient subjective estimate was that she felt better for a certain period of time, but in November 2020 her condition became worse, as she started to experience intense headaches and stronger effects of hemiparesis with affection of the facial nerve. Therefore, the patient travelled to Zagreb for an examination and an additional opinion related to her diagnosis and therapy. The diagnosis was confirmed and the patient was treated with bolus doses of methylprednisolone (1 x 1 gram/3 days), bolus doses of cyclophosphamide administered once a month and one of the recommendations was also a possible inclusion of biological drugs such as rituximab or infliximab. In our hospital, cyclophosphamide (1 gram/month) was included in the therapy. A control brain MRI was performed, which showed radiological regression, although there were signs of clinical progression. In the following period, three bolus doses of cyclophosphamide were administered to the patient, during which her condition was stable, but when it came to the fourth bolus dose of cyclophosphamide, the patient presented with significant clinical deterioration, with hemiplegia, more pronounced paralysis of the facial nerve, and constant and severe headache. She was prescribed a fourth bolus dose of cyclophosphamide, and it was recommended that she start using rituximab, because it is cheaper and easier to administer than infliximab, and both of these drugs are not on the positive list of medicaments covered by the health insurance. In April 2021, the patient received two doses of rituximab (1 g), after which she felt much better, she no longer had headaches, but the neurological deficit still occurred. In July 2021, the patient travelled to Turkey for an additional opinion regarding the diagnostics and therapy. Neuro-Behçet's disease was confirmed and therapy with azathioprine with glucocorticoids was recommended, but it was also recommended to include infliximab according to the schedule of infusion at 0, 2 and 6 weeks, and then every 8 weeks (8 mg/kg) with

terapiju. Bolesnica je neko vrijeme subjektivno bila bolje, no u studenom 2020. godine dolazi do pogoršanja u smislu intenzivne glavobolje i produbljivanja hemipareze s afekcijom facijalnog živca te bolesnica odlazi u Zagreb na pregled i dodatno mišljenje vezano za dijagnozu i terapiju. Dijagnoza je potvrđena, liječena je bolusima metil-prednizolona (1 x 1 gram/3 dana), preporučeni su i jednomjesečni bolusi ciklofosfamida te eventualno uključivanje biološke terapije rituksimabom ili infliksimabom. U našoj bolnici u terapiju je uključen ciklofosfamid (1 gram/mjesec). Učinjena je kontrolna MR mozga koja je pokazala radiološko stanje u regresiji, iako je kliničko stanje bilo u progresiji. U sljedećem periodu primijenjena su tri bolusa ciklofosfamida tijekom kojih je stanje bilo stabilno, ali kada je došao na red četvrti bolus ciklofosfamida bolesnica se prezentirala značajnim kliničkim pogoršanjem, s hemiplegijom, izraženijom paralizom facijalnog živca, stalnom i teškom glavoboljom. Propisan joj je i četvrti bolus ciklofosfamida, a preporučeno je da nabavi lijek rituksimab, jer je jeftiniji i jednostavnija je aplikacija zbog dolazaka u našu ustanovu od infliksimaba, a oba nisu na pozitivnoj listi Zdravstvenog osiguranja. U travnju 2021. godine bolesnica je primila dvije doze rituksimaba (1 g), nakon čega se osjećala puno bolje, više nije imala glavobolje, ali zaostao je neurološki deficit. U srpnju 2021. bolesnica odlazi u Tursku na dodatno mišljenje u vezi dijagnostike i terapije. Potvrđen je neuro oblik Behçetove bolesti i preporučena je terapija azatioprinom s glukokortikoidima, ali i preporuka da se uključi infliksimab prema shemi 0., 2., 6. tjedan, zatim svakih 8 tjedana (8 mg / kg TT) uz intenzivni fizikalno-terapijski tretman zbog neurološkog deficita. Početkom rujna 2021. bolesnica je ponovo otišla u Tursku, gdje je primila prve tri doze infliksimaba i bila podvrgnuta intenzivnom fizikalno-terapijskom tretmanu, koji je djelomično dao rezultate. Klinički tijek i odgovor na terapiju uz vrijeme izmjene terapije prikazani su na slici 3.

Međutim, nakon druge doze infliksimaba tijekom boravka u Turskoj pojavila se stafilodermija na malom dijelu kože, posebno na nogama i trupu, te je liječena antibioticima. Nakon treće infuzije infliksimaba bolesnica se vraća iz Turske u Bosnu i Hercegovinu. Preporučena je nastavak terapije azatioprinom 2 x 50 mg, metil-prednizolonom 1 x 4 mg i svakih 8 tjedana 8 mg/kg TT infliksimaba, koju treba nastaviti na našem odjelu.

Odmah po povratku bolesnica je dobila upalu pluća. U dva navrata bila je hospitalizirana u lokalnoj bolnici, a zatim upućena u našu kliniku u stanju pancitopenije s leukocitima  $0,44 \times 10^9/L$  i trombocitima  $39 \times 10^9/L$ , u septičnom stanju s opsežnim promjenama na plućima tipa akutnoga respiratornog distres sindroma (slika 4), teškom hipoproteinemijom i mineralnim disbalansom.



intensive physical therapy treatment due to neurological deficit. At the beginning of September 2021, the patient went to Turkey again, where she received the first three doses of infliximab and underwent intensive physical therapy treatment, which partially yielded results. The clinical course and response to therapy with the time of therapy change are shown in Figure 3.

However, after the second dose of infliximab which was administered during the patient's stay in Turkey, staphylococcal dermatitis appeared on a small area of the skin, especially on the legs and trunk, and the patient was treated with antibiotics. After the third infusion of infliximab, the patient returned from Turkey to Bosnia and Herzegovina. It was recommended to continue the therapy with azathioprine in a dose of 2 x 50 mg, methylprednisolone 1 x 4 mg and 8 mg/kg of infliximab every 8 weeks, which should be continued at our department.

Immediately upon her return, the patient developed pneumonia. On two occasions, she was hospitalized at a local hospital, and then referred to our Clinic in a state of pancytopenia with a leukocyte count of 0.44 x 10<sup>9</sup> /L and a platelet count of 39 x 10<sup>9</sup> /L, she was septic and had signs of extensive changes in the lungs pointing to acute respiratory distress syndrome (Figure 4), severe hypoproteinemia and mineral deficiency.

With the prescribed triple antibiotic therapy, antifungal therapy, immunoglobulins, glucocorticoids, granulocyte colony stimulating factor and other types of supportive therapy, there was a partial improvement in the patient's clinical and laboratory findings. On two occasions, the patient was intubated and connected to a ventilator due to hypoxemia. Polyuria with a diuresis occurred which was greater than 10 liters per day and there was possible development of diabetes insipidus due to the affected structures of the mesencephalon and diencephalon.

During stabilization at the respiratory level, severe abdominal pain occurred with the development of clinical features pointing to acute abdomen. Abdominal CT showed perforation of the small intestine, so the patient was transferred to another unit because she had

Uz propisanu trostruku antibiotsku terapiju, antifungalnu terapiju, imunoglobuline, glukokortikoide, faktore rasta granulocita i drugu suportivnu terapiju dolazi do djelomičnog poboljšanja kliničkih i laboratorijskih nalaza. U dva navrata bolesnica je intubirana i priključena na respirator zbog slabe saturacije kisikom. Pojavljuje se poliurija s diurezom preko 10 litara dnevno uz mogući razvoj dijabetesa insipidusa zbog zahvaćenih struktura mezencefalona i diencefalona.

Tijekom stabilizacije na respiratornoj razini javljaju se jaki bolovi u abdomenu s razvojem kliničke slike akutnog abdomena. CT abdomena pokazao je perforaciju tankog crijeva te je bolesnica prebačena na abdominalnu kirurgiju i učinjena je operacija kojom je verificirana perforacija tankog crijeva – jejunuma, a na području vaskulitisa (u sklopu Behçetove bolesti). Tijekom postoperativnog oporavka učinjen je aspirat traheobronhalnog stabla zbog promjena na CT-u pluća, koji je u međuvremenu učinjen, a postavi se sumnja na Kaposijev sarkom ili plućnu tuberkulozu. Uzorak je poslan na mikrobiološku analizu, gdje se potvrđuje mikroskopski pozitivan mikobakterium tuberkuloze. Nakon toga se započne liječenje antituberkuloznom terapijom na Klinici za plućne bolesti i tuberkulozu kroz mjesec dana. Postoperativna rana na prednjoj trbušnoj stijenci, koja se redovito čistila, nije zacjeljivala „per primam“, no na kraju je najvjerojatnije to bila ulazna točka nekog patogenog uzročnika koji je doveo do razvoja septičkog šoka i smrtnog ishoda 1. veljače 2022.

## RASPRAVA

Behçetova bolest je izuzetno rijetka na našim prostorima, a neuro oblik bolesti još je rjeđi. Prisutnost neuroloških manifestacija u sklopu Behçetove bolesti naziva se neuro-Behçetova bolest ili sindrom. Češće se javlja u muškaraca nego u žena i obično počinje u trećem desetljeću života. Nazvana je i bolešću „puta svile“ jer je incidencija na tom području Euroazije, od Indokine preko Irana do Turske znatno viša nego u ostalim područjima. Rijetko neurološke manifestacije počinju

to undergo abdominal surgery. Following that, surgery was performed to verify perforation of the small intestine – jejunum, in the area affected by vasculitis (as part of Behçet's disease). During the patient's postoperative recovery, aspiration of the tracheobronchial tree was performed due to changes noticed on the lung CT, which was performed in the meantime, and Kaposi's sarcoma or pulmonary tuberculosis were suspected. The sample was sent for microbiological analysis, where mycobacterium tuberculosis was confirmed through microscopic tests. After that, treatment with antituberculosis therapy started at the Clinic for Pulmonary Diseases and Tuberculosis and it lasted for one month. The post-operative wound on the anterior abdominal wall, which was regularly cleaned, did not heal during primary wound healing ("sanatio per primam intentione"), but in the end it was most likely the entry point of some pathogenic agent that led to the development of septic shock and the patient's death on February 1st, 2022.

## DISCUSSION

Behçet's disease is extremely rare in our region, and the neuro-Behçet's disease is even more rare. The presence of neurological manifestations as part of Behçet's disease is called neuro-Behçet's disease or neuro-Behçet's syndrome. It occurs more often in men than in women and usually begins in the third decade of life. It was also called the "Silk Road" disease because its incidence in that area of Eurasia, from Indochina, through Iran all the way to Turkey, is significantly higher than in other areas. Neurological manifestations of this disease rarely occur before others (only in 6% of patients), and they usually appear after the basic signs and symptoms of the disease. Involvement of the cerebral hemispheres and basal ganglia causes more severe clinical features and a worse prognosis of the final outcome. The presence of the HLA-B51 gene also worsens the prognosis of the disease (10). Early initiation of therapy with high doses of glucocorticoids and the addition of another immunosuppressive drug in younger patients yields good results, in contrast to older patients with neuro-Behçet's disease (11), but sometimes exceptions are found when, despite the therapy that has been administered and the use of second or possibly the third medication (or every subsequent medication), the condition worsens with the appearance of various complications, both within the disease itself and due to immunosuppressive therapy. So, despite pre-therapeutic treatment, such as markers for hepatitis B and C, Quantiferon test for latent tuberculosis, radiological and ultrasound examinations, complications may develop as a result of immunosuppression. It is particularly important to monitor the possibility of developing complications when using immunosup-

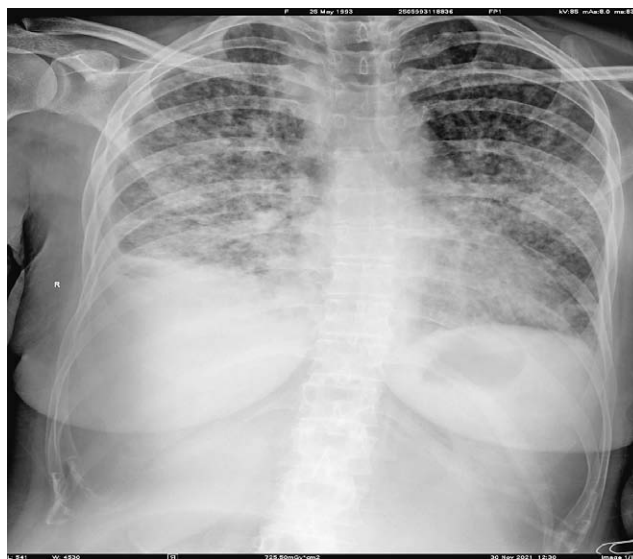


FIGURE 4 Radiography of the heart and lungs after infliximab therapy (third dose of the drug). Acute respiratory distress syndrome

SLIKA 4. Radiografija srca i pluća nakon terapije infliksimabom (treća doza lijeka). Akutni respiratorni distress sindrom.

prije ostalih (samo u 6% bolesnika), obično se javljaju nakon osnovnih znakova i simptoma bolesti. Zahvaćenost hemisfera velikog mozga i bazalnih ganglija uzrokuje težu kliničku sliku i lošiju prognozu konačnog ishoda. Prisutnost gena HLAB51 također pogoršava prognozu bolesti (10). Rano započinjanje terapije visokim dozama glukokortikoida i dodavanje drugoga immunosupresivnog lijeka u mlađih bolesnika daje dobre rezultate, za razliku od starijih bolesnika s neuro-Behçetovom bolešću (11), ali ponekad se nađu iznimke kada se unatoč terapiji koja je primijenjena te primjeni drugog, eventualno trećeg ili svakog sljedećeg lijeka stanje pogoršava pojavom raznih komplikacija, kako u sklopu same bolesti, tako i od immunosupresivne terapije. Dakle, unatoč predterapijskoj obradi, kao što su markeri na hepatitis B i C, quantiferonski test na latentnu tuberkulozu, radiološke i ultrazvučne pretrage, mogu se razviti komplikacije kao posljedica immunosupresije. Osobito je važno pratiti mogućnost razvoja komplikacija pri primjeni immunosupresivne i biološke terapije, neovisno o tome koliko je bila dobra priprema za njezino uključivanje ili vremenski period propisivanja. Mali broj oboljelih od ove bolesti na našim prostorima, posebice s težim oblicima bolesti, ne daje nam dovoljno prostora za stvaranje osobnog iskustva u liječenju ovako teških stanja, već smo prisiljeni osloniti se na radove i iskustva drugih.

Ovim radom željeli smo prikazati izazove koji su pratili prilikom odlučivanja o adekvatnom terapijskom pristupu s najboljim terapijskim učincima u bolesnice s neuro-Behçetovom bolešću. Još uvijek smo u dvojbi koji će lijek dati najbolje rezultate i imati najmanje

pressants and biological drugs, regardless of the preparation for the inclusion of that therapy or the period when this therapy was prescribed. The small number of people suffering from this disease in our region, especially with more severe forms of the disease, does not give us enough space to create personal experience in the treatment of such difficult conditions. Instead, we are forced to rely on the studies and scientific papers conducted and written by others, as well as their experiences.

In this paper, we wanted to present the challenges that we were faced with in the process of selecting an adequate therapeutic approach with the best therapeutic effects in patients suffering from neuro-Behçet. There is still doubt as to which drug will yield the best results and have the fewest complications, when is the best time to start introducing immunosuppressive or biological therapy and how aggressive should it be, and what can we expect from the therapy that was introduced.

**ACKNOWLEDGMENTS:** The authors report no acknowledgments.

**FUNDING:** For this work authors did not receive any funding.

**CONFLICT OF INTEREST STATEMENT:** The authors declare no conflict of interest.

komplikacija, kada i koliko agresivno započeti s imunosupresivnom ili biološkom terapijom i koliko možemo očekivati od uključene terapije.

**ZAHVALA:** Autori nisu naveli zahvale za ovaj rad.

**FINANCIRANJE:** Autori za ovaj rad nisu primili nikakva sredstva.

**IZJAVA O SUKOBU INTERESA:** Autori izjavljuju da nisu u sukobu interesa.

## REFERENCES / LITERATURA

1. Akman-Demir G, Serdaroglu P, Taşçi B. Clinical patterns of neurological involvement in Behçet's disease: evaluation of 200 patients. The neuro-Behçet study group. *Brain*. 1999;122:2171–82.
2. Davatchi F. Diagnosis/classification criteria for Behçet's disease. *Pathology Research International*. 2012; article ID 607921, 5 pages. <https://doi.org/10.1155/2012/607921>.
3. Gonul M, Pelin Kartal S, eds. Behçet's Disease. Rijeka: In Tech; 2017. 210 p.
4. Woźniacka A, Sysa-Jędrzejowska A, Jurowski P, Jabłkowski M, Kot M. Morbus Behçet – a rare disease in Central Europe. *Arch Med Sci*. 2015;11(6):1189–96.
5. Borhani-Haghighi A, Kardeh B, Banerjee S, Yadollahikhales G, Safari A, Sahraian MA et al. Neuro-Behçet's disease: An update on diagnosis, differential diagnoses, and treatment. *Mult Scler Relat Disord*. 2020;39:101906. doi: 10.1016/j.msard.2019.101906.
6. Akman-Demir G, Mutlu M, Kiyat-Atamer A, Shugaiv E, Kurtuncu M, Tugal-Tutkun I et al. Behçet's disease patients with multiple sclerosis-like features: discriminative value of Barkhof criteria. *Clin Exp Rheumatol*. 2015;33(6 Suppl. 94):S80–4.
7. Ozyurt S, Sfrikakis P, Siva A, Constantinescu CS. Neuro-Behçet's disease – clinical features, diagnosis and differential diagnosis. *European Neurological Review*. 2018;13(2):93–7. DOI: <https://doi.org/10.17925/ENR.2018.13.2.93>
8. Akman-Demir G Saip S, Siva A. Behçet's Disease. *Curr Treat Options Neurol*. 2011;13(3):290–310.
9. Zhao C, Li C, Duan FJ, Yan Q, Zhang Z, Du Y. Case report: repeated low-dose rituximab treatment is effective in relapsing Neuro Behçet's disease. *Front Neurol*. 2021;12:595984.
10. Noel N, Bernard R, Wechsler B, Resche-Rigon M, Depaz R, Le-Thi Huong Boutin D et al. Long-term outcome of neuro-Behçet's disease. *Arthritis Rheumatol*. 2014;66(5):1306–14. doi: 10.1002/art.38351.
11. Sorgun MH, Kural MA, Yücesan C. Clinical characteristics and prognosis of Neuro-Behçet's disease. *Eur J Rheumatol*. 2018;5(4): 235–9. doi: 10.5152/eurjrheum.2018.18033.